



**PATIENT PRESENTING CLINICAL SIGNS**

Sammy Sterite

History: Recheck echo. History mitral valve dysplasia with LVOTO. On Atenolol 6.25mg SID. BP: 140mmHg.\*Sedated with Gabapentin and 0.1ml Butorphanol.  
-Pertinent previous echo findings (10/31/22 MML): LA 1.0 cm, LA:Ao 0.9, IVS 0.63 cm, PW 0.62 cm. Normal LA size.

**SPECIES**

Feline

**ECHOCARDIOGRAM FINDINGS**

2D, m-mode, color flow and Doppler imaging is available.

**BREED**

DLH

**Left ventricle:** The LV diameter is normal with adequate myocardial function. The LV wall thicknesses are normal with regions of borderline hypertrophy. There is a mildly hyperechoic endocardium consistent with mild fibrosis. The papillary muscles appear normal. The endocardium is normal.

**SEX**

Male Neutered

**Left atrium:** The left atrium is normal. No spontaneous contrast or thrombi seen.

**Mitral valve:** The anterior leaflet of the mitral valve is mildly thickened and elongated. No anterior motion is seen during systole. No mitral regurgitation.

**AGE**

2.9 years

**Aortic valve/Aorta:** The aortic valve is normal in morphology and mobility. The aortic root is dilated. Normal LVOT outflow velocity. No aortic insufficiency.

**Right ventricle:** Normal right ventricular diameter and morphology indicating no overt evidence of pulmonary arterial hypertension.

**Right atrium:** The right atrium is normal in dimension.

**WEIGHT**

11lbs

**Tricuspid valve:** The tricuspid valve appears normal with no tricuspid regurgitation.

**Pulmonary valve/Pulmonary artery:** The pulmonic valve is normal in morphology and mobility. No pulmonic insufficiency. Normal RVOT velocity; laminar flow.

**Pericardium/other:** No pericardial or pleural effusion noted. No obvious cardiac masses.

**INTERPRETED BY**

Maggie Machen  
Lamy, DVM  
DACVIM (Cardiology)

**Heart rhythm:** ECG reveals a sinus rhythm with an average HR of 120bpm.

**2-Dimensional Measurements**

Ao diam (cm)	1.1
LA diam (cm)	1.2
LA:Ao (Swe)	1.1
IVS thickness (cm)	0.49
LVID diastole (cm)	1.4
PW thickness (cm)	0.44
LVID systole (cm)	0.4
FS (%)	72

**Doppler Measurements**

PV Vmax (m/s)	0.72
AoV Vmax (m/s)	1.0
MR Vmax (m/s)	NA
TR Vmax (m/s)	NA
TR PG (mmHg)	NA

**IMAGING**

**PERFORMED BY**

Pamela Harrigan,  
RDCS

**INTERPRETATION OF THE FINDINGS**

Compared to the prior study, there is evidence of improvement on Atenolol therapy. Previously mild hypertrophy has resolved, and the LA remains normal. The LVOTO appears well controlled, and no additional issues are identified.

**HOSPITAL NAME**

VCA Hansen Animal  
Hospital

**REFERRING VET**

Dr. Whalen

Prognosis remains guarded long-term; however, this is certainly a good sign. Patient may be at risk for progression in the future despite improvement seen here. No additional medications are indicated at this time.

**INVOICE**

30131

**DATE**

4/10/23



**PATIENT**

Sammy Sterite

**SPECIES**

Feline

**BREED**

DLH

**SEX**

Male Neutered

**AGE**

2.9 years

**WEIGHT**

11lbs

**INTERPRETED BY**

Maggie Machen  
 Lamy, DVM  
 DACVIM (Cardiology)

**IMAGING PERFORMED BY**

Pamela Harrigan,  
 RDCS

**HOSPITAL NAME**

VCA Hansen Animal  
 Hospital

**REFERRING VET**

Dr. Whalen

**INVOICE**

30131

**DATE**

4/10/23

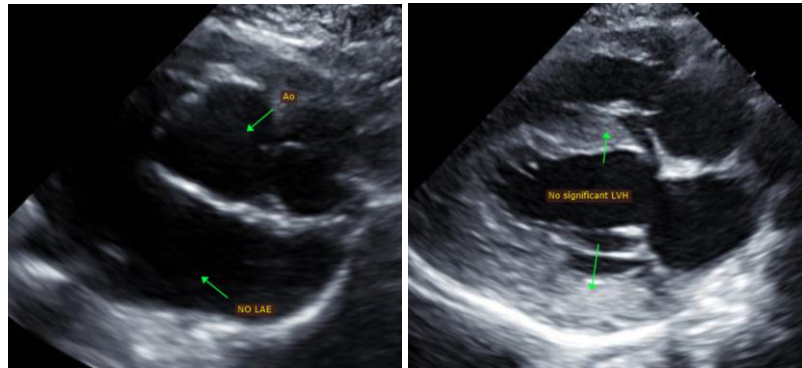
**RECOMMENDATIONS**

- Baseline BP recommended every 6-12 months.
- Continue Atenolol as prescribed.
- Anesthetic risk is considered mildly elevated, however judicious IV fluid rates are advised to avoid fluid overload. Additionally, drugs that stimulate heart rate should be avoided unless clinically necessary (glycopyrrolate, atropine). Avoid vasodilators as this may worsen the obstruction. A reasonable protocol includes opioid/benzodiazepine premedication, propofol induction, isoflurane maintenance.
- Monitor for any clinical evidence of cardiac compromise, including respiratory changes and/or signs of a blood clot event (paralysis, neurologic changes, etc.).

**PLAN**

- Recommend recheck echocardiogram annually, sooner if any clinical signs arise.

**IMAGES**



The information and recommendations provided are based on the images presented by the referring veterinarian. No evaluation can be communicated regarding pathology that was not visible in the image/video clips provided.

Thank you for this referral. This report was generated using transcription software, and minor dictation errors may be present. If the clinical or image interpretation does not parallel your findings or if I can be of any further assistance, please contact me.

Maggie Machen Lamy, DVM  
 Diplomate of the American College of Veterinary Internal Medicine (Cardiology)  
 info@sonopath.com

Echocardiogram performed by: Pamela Harrigan, RDCS  
 Pet Animal Ultrasound Service ([4paus.com](http://4paus.com))